
AUTOMATED SCOLIOSIS ASSESSMENT FROM SPINE X-RAY USING GENERATIVE ADVERSARIAL NETWORKS (GANs)

¹Mr. S. Chandra Shekher, ²K. Reetwika, ³K. Sneha Latha, ⁴D. Krishna Sri, ⁵Ch. Laxmi
Vaishnavi

¹Assistant Professor, Department of Information Technology
^{2,3,4,5}B. Tech 4th Year Students, Department of Information Technology, Vignan's Institute of
Management and Technology for Women, Hyderabad, Telangana – 501301, India.

[1ChandraSheker@vmtw.in](mailto:ChandraSheker@vmtw.in), [2reetwika2004@gmail.com](mailto:reetwika2004@gmail.com), [3snehalathakura@gmail.com](mailto:snehalathakura@gmail.com),
[4krishnasridachepally@gmail.com](mailto:krishnasridachepally@gmail.com), [5vaishnavichalapati93@gmail.com](mailto:vaishnavichalapati93@gmail.com)

ABSTRACT

Scoliosis, a lateral or S-shaped curvature of the spine, needs to be diagnosed accurately and as early as possible for effective treatment. Conventional assessment relies on the manual measurement of Cobb angle which is a labour-intensive process potentially subject to human error. We propose a novel two-phase Generative Adversarial Networks (GAN) based method for automatic scoliosis evaluation in this work. We propose the first stage of a GAN based model to specifically segment the spine, which is then followed by a second stage in which the main clinical features such as the Cobb angles are extracted and analysed to evaluate how severe the curvature is. The model, which is trained on labelled spine X-ray datasets, shows high accuracy in segmentation and scoliosis. We present a model trained on labelled datasets of spine X-rays, that has high segmentation accuracy and scoliosis classification and reduces manual analysis. The experimental findings reaffirm the strength of this framework, and highlight its possibilities for integration into clinical routine in order to improve diagnostic accuracy and minimize the existence of unnecessary imaging.

Keywords: Scoliosis, Spine Segmentation, GAN, Cobb angle measurement, Medical imaging, Clinical diagnosis.

1. INTRODUCTION

Scoliosis is a spinal disorder characterized by an abnormal curvature of the spine, typically diagnosed using spinal X-ray images. The severity of scoliosis is commonly measured using the Cobb angle, which is traditionally calculated manually by clinicians. However, manual measurement can be time-consuming and may lead to variability due to subjective interpretation. To address these limitations, this study proposes an AI-based approach for automated spine segmentation and Cobb angle estimation from X-ray images. By applying deep learning techniques, the system aims to improve measurement consistency, reduce manual effort, and assist clinicians in the early and accurate assessment of scoliosis. The proposed system utilizes advanced image processing and deep learning models to analyse spinal structures effectively. This approach demonstrates the potential of artificial intelligence in supporting medical diagnosis and improving the healthcare efficiency.



International Journal of DATA SCIENCE AND IOT MANAGEMENT SYSTEM

Peer Reviewed, Referred & Indexed Journal

ISSN: 3068-272X

www.ijdim.com

Original Research Paper

detect scoliosis.

d. Model Training

The dataset is divided into training and testing sets. The GAN model is trained using deep learning frameworks such as TensorFlow and PyTorch. During training, the generator learns to produce realistic images while the discriminator learns to distinguish between real and generated images. This iterative learning process improves the model performance.

e. Cobb Angle Calculation

The Cobb Angle is used to measure the degree of spinal curvature in scoliosis from an X-ray image. Mathematically, if the slopes of the two vertebral lines are m_1 and m_2 , the cobb angle can be calculated using this formula –

$$\theta = \tan^{-1} ((m_1 - m_2) / (1 + m_1 m_2))$$

4. ALGORITHM

1. Image Acquisition and Preprocessing:

- a. Collect spinal X-ray images from datasets or hospitals
- b. Resize images to a fixed resolution
- c. Remove noise using filtering techniques
- d. Improve visibility of the spine

2. Spine Segmentation Using GAN:

- a. Generates the spine segmentation mask
- b. Checks if the mask is real or generated
- c. Final spinal region is obtained

3. Feature Extraction and Landmark Detection:

- a. Detect boundaries of the spine
- b. Identify upper and lower vertebrae
- c. Locate key spinal points

4. Cobb Angle Calculation and Classification:

- a. Draw lines on upper and lower vertebrae
- b. Calculate the Cobb Angle
- c. Classify as Normal, Mild, Moderate or severe scoliosis

5. RESULT

USER INTERFACE:

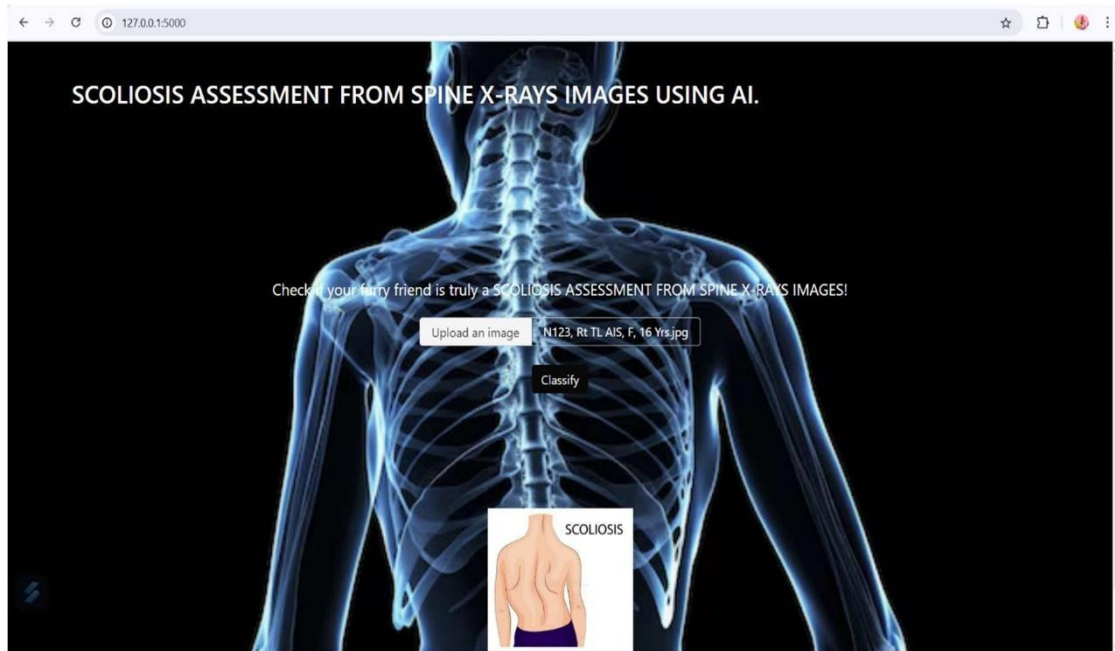


Fig. 1. User Interface

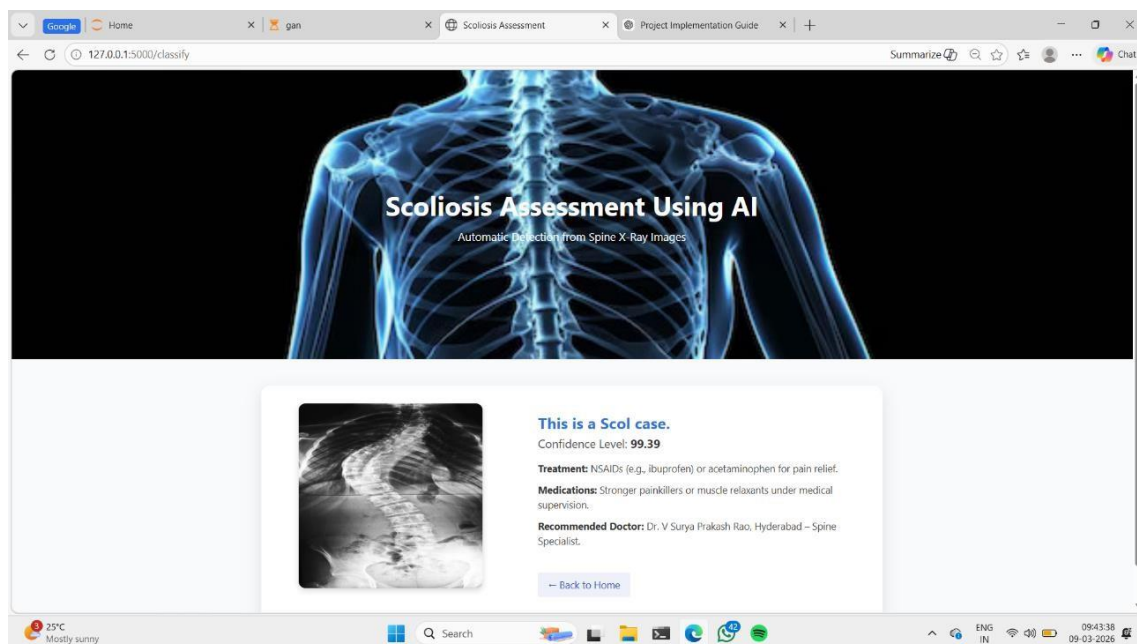


Fig. 2. Scoliosis Case

1. After uploading a spinal X-ray image showing a scoliosis spine, the system preprocesses the image and uses GAN for spinal segmentation which then identifies upper and lower vertebrae. These are used to calculate the Cobb Angle, in this case, the angle is greater than 10 degrees the system classifies the condition as “**Scoliosis Case**”.

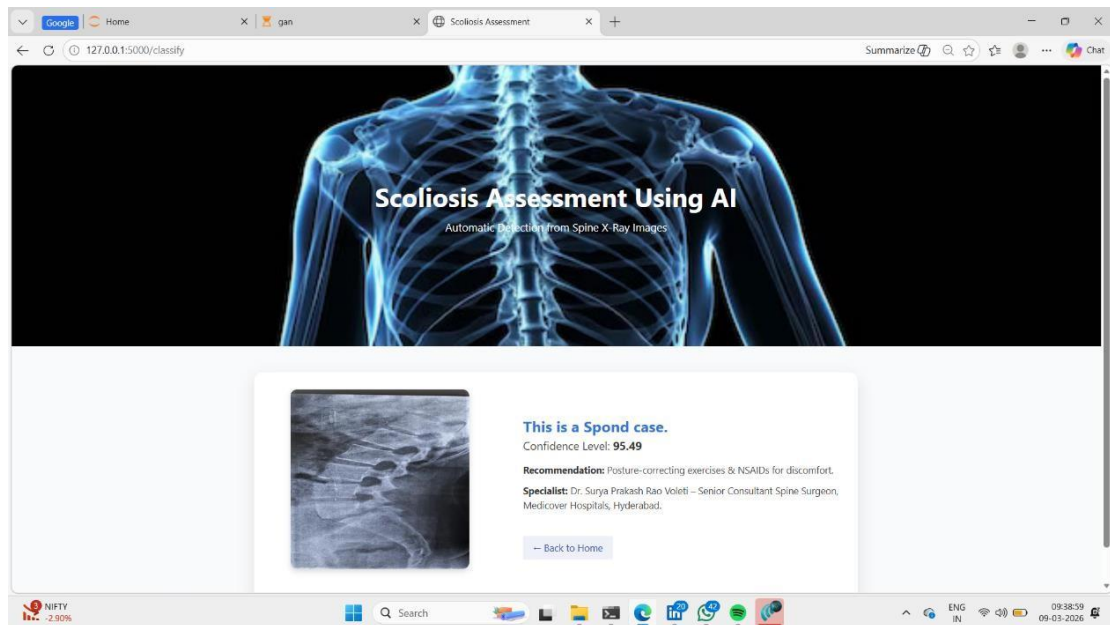


Fig. 3. Spondylosis Case

2. After uploading a spinal X-ray image showing a spondylosis spine, the system preprocesses the image and uses GAN for spinal segmentation which then identifies upper and lower vertebrae. If there is any irregularity in the spine such as reduced disc space or any structure change in the spine, then the system classifies the condition as “**Spondylosis Case**”

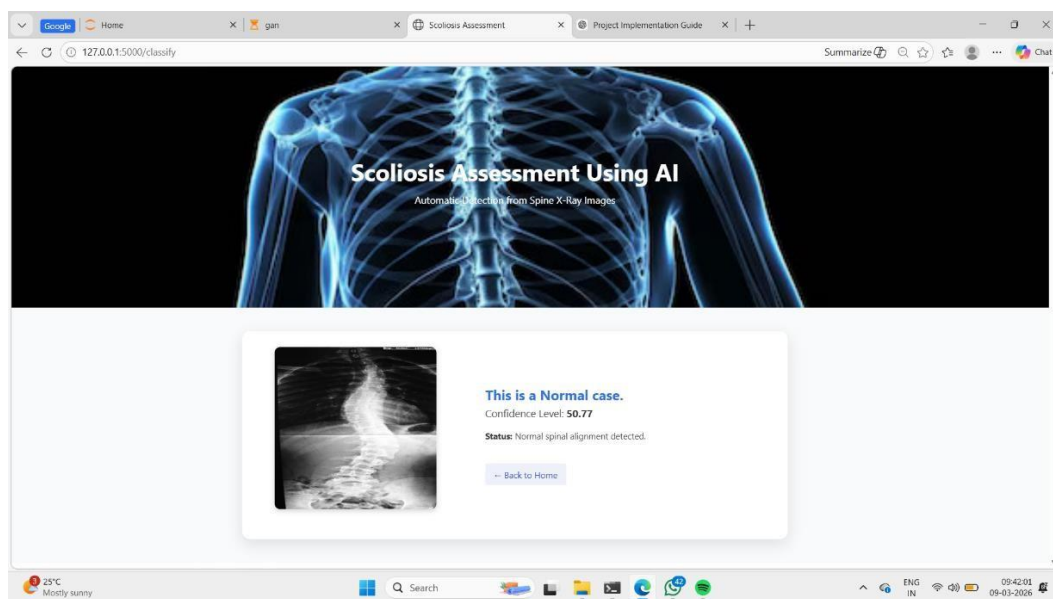


Fig. 4. Normal Case

3. After uploading a spinal X-ray image showing a normal spine, the system preprocesses the image and uses GAN for spinal segmentation which then identifies upper and lower vertebrae. These are used to calculate the cobb angle, in this case, the angle is less than 10 degrees the system classifies the condition as “**Normal Case**”.

6. CONCLUSION

This Paper shows the implementation of how deep learning is used especially Generative Adversarial Networks (GANs) to detect the curvature of the spine using the X-Ray image which is uploaded. This project detects the three cases of the spinal which are the normal case, scoliosis case and the spondylosis case. It reduces the manual work done by the doctors like image processing, spinal segmentation, removing unwanted marks and calculating cobb angle. The system mainly reduces the human error and gives a consistent result. This project is very accurate and reliable when tested with different X-ray images, it also helps to assist doctors.

7. FUTURE SCOPE

One of the primary areas of future development is multi-modal input integration, which involves incorporating MRI or CT scans along with X-ray images to improve anatomical interpretation in complex cases. Additionally, we can deploy the system as cloud-based solution which would enhance the accessibility of the remote clinics. The system can also be extended to analyse the 3D spinal images, which helps in deeply understanding the complex spinal problems. Once when the system is integrated with the hospital database the doctor can easily access the patient reports and the X-ray images from different locations. Creating a mobile or cloud-based version of the system for remote diagnostics and telemedicine applications may also be considered for future enhancement.

8. REFERENCES

- [1] H. Kim, H. S. Kim, E. S. Moon, C. S. Yoon, T. S. Chung, H. T. Song, et al., "Scoliosis imaging: what radiologists should know," *Radiographics*, vol. 30, pp. 1823–1842, 2010.
- [2] J. W. Roach, "Adolescent idiopathic scoliosis," *Orthop. Clin. North Am.*, vol. 30, pp. 353–365, 1999.
- [3] L. Baert, *Spinal Imaging: Diagnostic Imaging of the Spine and Spinal Cord*, Berlin: Springer Science & Business Media, 2007.
- [4] F. E. Silva and L. G. Lenke, "Adolescent idiopathic scoliosis," in *Surgical Management of Spinal Deformities*, T. J. Errico, B. S. Lonner, and A. W. Moulton, Eds. Philadelphia: Saunders Elsevier, 2009, pp. 97–118.
- [5] S. L. Weinstein, D. C. Zavala, and I. V. Ponseti, "Idiopathic scoliosis: long-term follow up and prognosis in untreated patients," *J. Bone Joint Surg. Am.*, vol. 63, pp. 702–712, 1981.

- [6] D. Malfair, A. K. Flemming, M. F. Dvorak, P. L. Munk, A. T. Vertinsky, M. K. Heran, et al., "Radiographic evaluation of scoliosis: review," *AJR Am. J. Roentgenol*, vol. 194, pp. S8–S22, 2010.
- [7] J. E. Pruijs, M. A. Hageman, W. Keessen, R. van der Meer, and J. C. van Wieringen, "Variation in Cobb angle measurements in scoliosis," *Skeletal Radiol.*, vol. 23, pp. 517–520, 1994.
- [8] R. T. Morrissy, G. S. Goldsmith, E. C. Hall, D. Kehl, and G. H. Cowie, "Measurement of the Cobb angle on radiographs of patients who have scoliosis. Evaluation of intrinsic error," *J. Bone Joint Surg. Am.*, vol. 72, pp. 320–327, 1990.
- [9] F. Galbusera, F. Niemeyer, H. J. Wilke, T. Bassani, G. Casaroli, C. Anania, et al., "Fully automated radiological analysis of spinal disorders and deformities: a deep learning approach," *Eur. Spine J.*, vol. 28, pp. 951–960, 2019.
- [10] R. H. Alharbi, M. B. Alshaye, M. M. Alkanhal, N. M. Alharbi, M. A. Alzahrani, and O. A. Alrehaili, "Deep learning-based algorithm for automatic scoliosis angle measurement," in *Proc. 2020 3rd Int. Conf. Comput. Appl. Inf. Secur. (ICCAIS)*, Riyadh, Saudi Arabia, 2020, pp. 1–5.